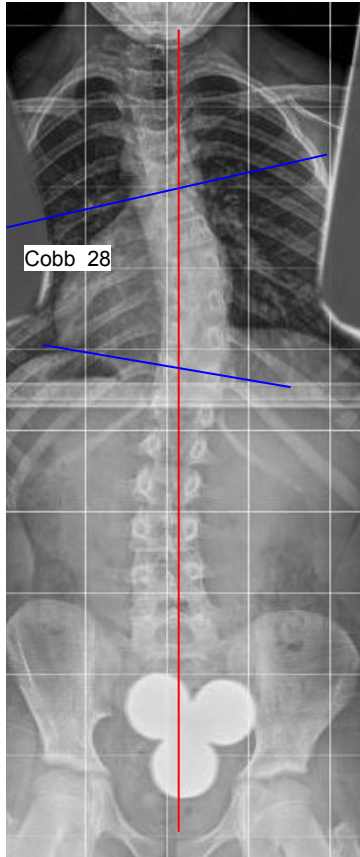


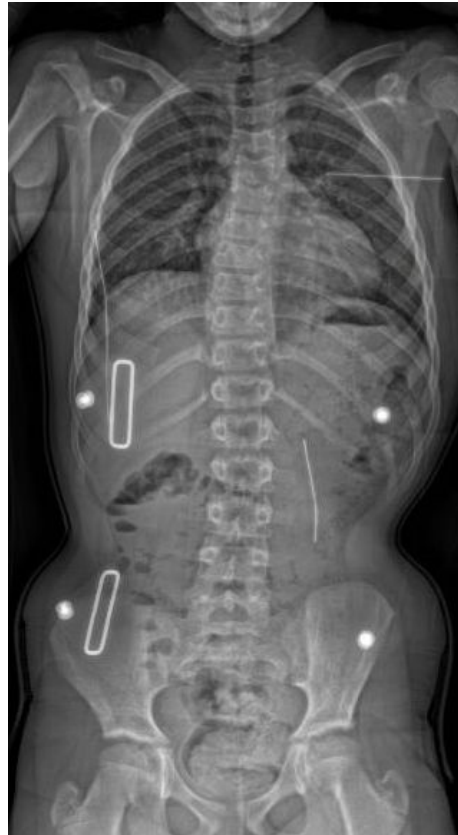# Schrothpdx website case study

Kim Osterberger, DPT

Before treatment



With WRC Brace



Without brace/ After 6 months of bracing and Schroth

